

PATIENT PRESENTING CLINICAL SIGNS

Emerald Lodati
History: Increased respiratory rate, suspect heart failure
Medication: 6.25 Lasix BID, Methimazole 2.5 BID
BP: 134/92, 139/81, 143/82

SPECIES

Feline

ECHOCARDIOGRAPHIC FINDINGS

Multiple 2D, M-mode, and Doppler video loops and still images are submitted for review.

BREED

DSH

There is moderate left atrial dilation. The mitral valve appears normal, though mild mitral regurgitation is present. Left ventricular wall thickness is normal. Left ventricular internal dimensions are normal. Left ventricular systolic function is hyperdynamic. The aorta and aortic valve are normal. Right atrial and right ventricular dimensions are normal. The tricuspid valve is normal. The pulmonary artery and pulmonic valve are normal. No pericardial effusion or cardiac masses are seen.

SEX

FS

AGE

14 years

LA/Ao - 2.30
IVSd - 4.2 mm
LVPWd - 4.2 mm
LVIDd - 15.8 mm
LVIDs - 7.1 mm

WEIGHT

10.5#

FS - 55%
LVOT - 0.92 m/s
RVOT - 0.87 m/s

INTERPRETED BY

Keith Blass, DVM,
MS, DACVIM

ASSESSMENT/RECOMMENDATIONS

This examination demonstrates moderate dilation of Emerald's left atrium, with differentials for this finding including a restrictive cardiomyopathy (RCM), atrial myopathy, cardiac thyrotoxicosis, or a combination of one or more. Given the presence of moderate dilation, it's very likely that Emerald's pleural effusion is the result of the development of congestive heart failure (CHF). In addition to CHF, Emerald is at risk for cardiac thrombus formation with secondary thromboembolic disease, as well as arrhythmia formation, therefore, careful monitoring for the development of clinical signs associated with these conditions is recommended.

IMAGING PERFORMED BY

Rebekah Jakum, CVT
ARDMS/RVT

Thoracocentesis is recommended to rapidly improve Emerald's respiratory rate/effort.

HOSPITAL NAME

Pocono Peak VC

Continued use of furosemide is warranted at this time. Most cats experiencing CHF for the first time will do well with a dose of 6.25 mg BID, though it's possible that a higher dose may be needed for Emerald. I also recommend starting Emerald on enalapril (1.25 mg BID) and clopidogrel (18.75 mg SID).

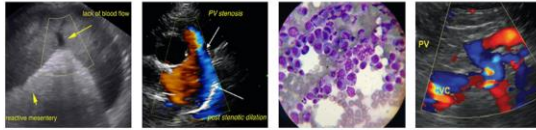
REFERRING VET

Dr. Santore

Recheck radiographs and a renal/electrolyte profile are recommended in 1 week. A recheck echocardiogram is recommended in 6 months.

DATE

2.25.2022



PATIENT

Emerald Lodati

SPECIES

Feline

BREED

DSH

SEX

FS

AGE

14 years

WEIGHT

10.5#

INTERPRETED BY

Keith Blass, DVM,
MS, DACVIM

IMAGING PERFORMED BY

Rebekah Jakum, CVT
ARDMS/RVT

HOSPITAL NAME

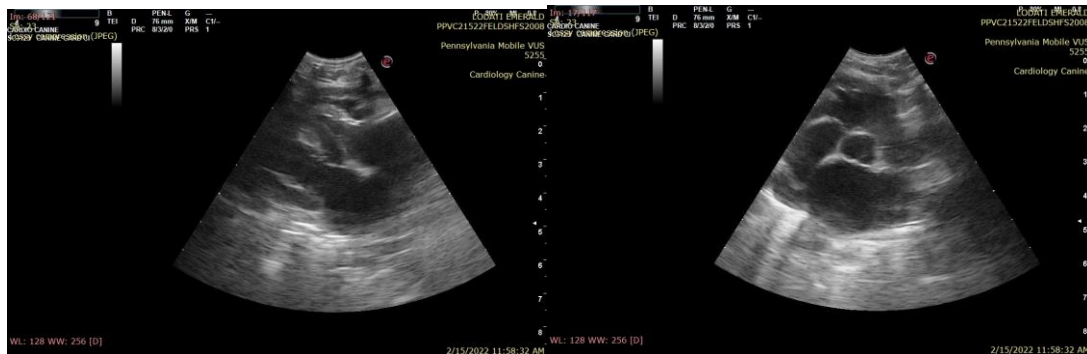Pocono Peak VC

REFERRING VET

Dr. Santore

DATE

2.25.2022



The information and recommendations provided are based on the images presented by the referring veterinarian. No evaluation can be communicated regarding pathology that was not visible in the image/video clips provided.

Thank you for this referral. If the clinical or image interpretation does not parallel your findings or if I can be of any further assistance please contact me.

Keith Blass, DVM, MS, DACVIM (Cardiology)
KeithBlass@gmail.com
631-804-5754